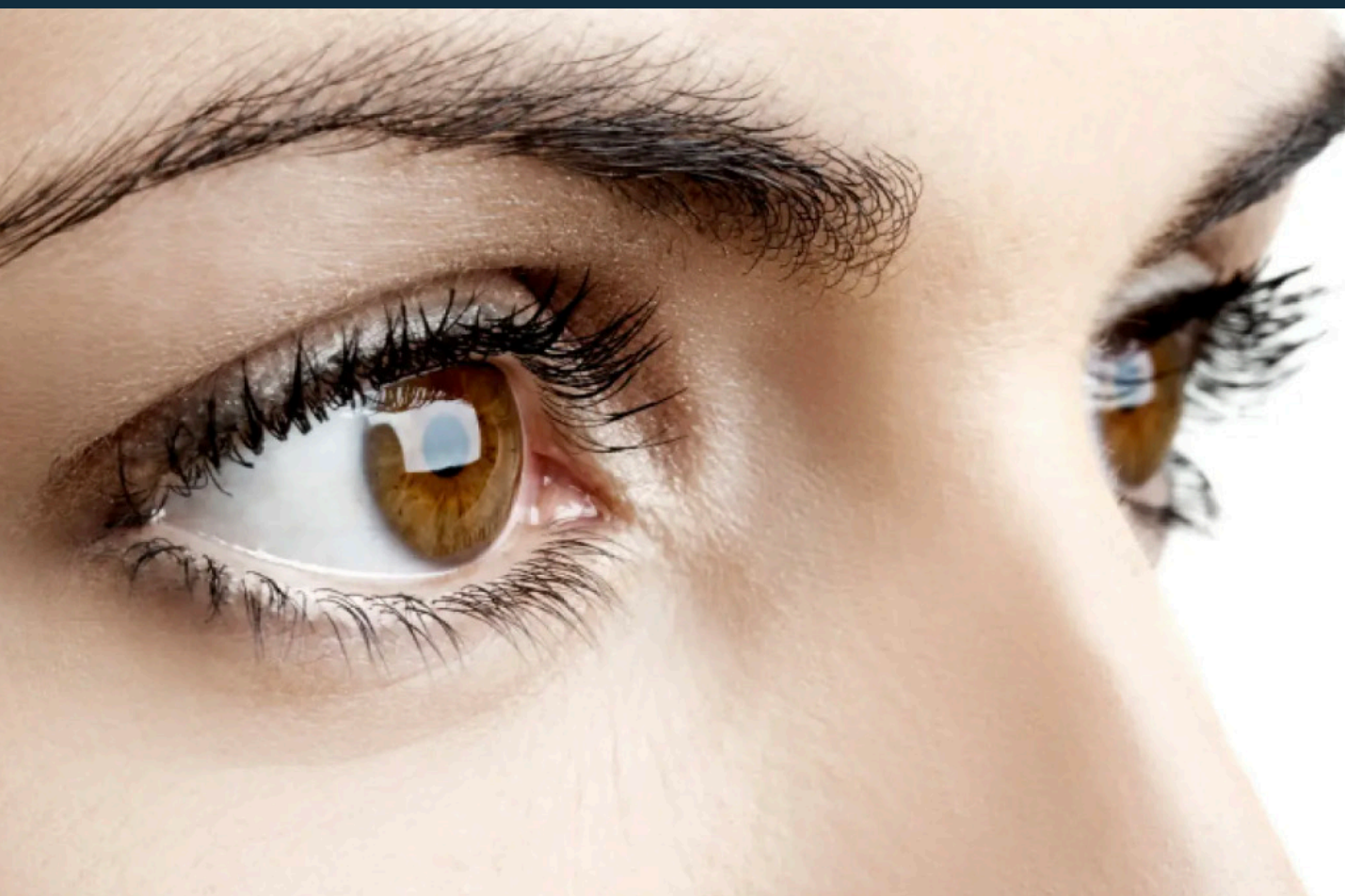



# DORNN EYE CARE

DR. BRUCE DORNN • OPTOMETRIST



CASE STUDY RESOURCE  
2023



## ABOUT THE AUTHOR

Dr. Bruce Dornn was born and raised in Southern California. He graduated from the New England College of Optometry in Boston, MA, and is a member of the AOA, CAO and MAO. He maintains an Optometric license in both the United States and Canada. Dr. Dornn practiced in Denver Colorado for several years before moving to Canada where he founded Dornn Eye Care. Over the last 15 years, he developed a Dry Eye Center of excellence and founded Eye-Revive Inc. which offers an extensive line of dry eye products as well as practice management resources and educational courses for Optometrists interested in starting a dry eye specialty.

*All content contained in this document is the intellectual property of Dr. Dornn and cannot be duplicated without prior written consent.*

Dr. Bruce Dornn  
bruce@eye-revive.ca

DR. B. DORN

# CASE STUDY 1 :

## Meibomian Gland Dysfunction (MGD)

DIAGNOSIS: MGD WITH COMPUTER VISION SYNDROME

Age: 50 yrs old  
Gender: Female  
Occupation: Communications Director

### HISTORY

1st presented in 2016 and only wanted prescription for Restasis

NIK BUT with K5M; OD 6.51 OS 9.04

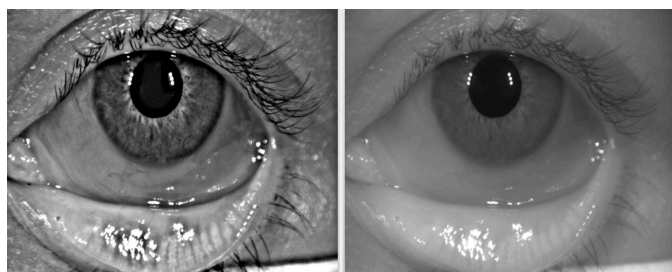
F/U in 2017:

NIK BUT: OD 6.65 and OS 8.03 and reported no improvement in symptoms

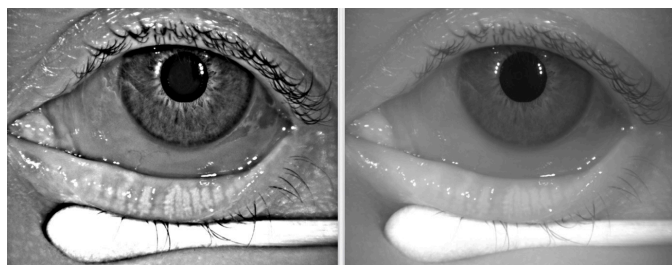
*Returned for dry eye consult and proceeded with treatments using Forma-I and Lumecca-I.*

### DIAGNOSTIC TOOLS

- K5M
- NIK BUT
- Meibography
- Fluorescein with photo and video
- Slit lamp
- Inflammadry



Pre-Tx OS



Post-Tx OS

### SYMPTOMS

- Dry eyes
- Problem with focus and intermittent blur intolerance to contact lens wear (discontinued wearing her contact lenses)

### TREATMENT

- Lid hygiene with Gentle Tea Tree Cleanser
- Moist hot compresses: 20 min/day
- Treatment with Lumecca-I and Forma-I with gland expression: 4 treatments every 4 weeks

### IMPROVED DIAGNOSTICS

NIK BUT:

Pre-Tx OD 6.51 improved to 13.3 (post Tx)

Pre-Tx OS 9.04 improved to 15.1 (post Tx)

*Improved meibomian gland health with no inflammation.*

### RESULTS

Meibography shows significant improvement in meibomian gland health. Patient is very happy with the comfort of the treatments. She is no longer using any drops and follows an at-home maintenance regime of moist heat and Tea Tree cleanser.

# CASE STUDY 2 :

## Auto-immune Dry Eye Disease

DIAGNOSIS: LAGOPHTHALMOS, JUVENILE RHEUMATOID ARTHRITIS

**Age:** 23 yrs old  
**Gender:** Female  
**Occupation:** Engineering Student

### HISTORY

---

Patient tried Restasis, but discontinued.  
Tried Xiidra with very little improvement.

### DIAGNOSTIC TOOLS

---

- K5M
- Slit lamp examination
- Inflammadry

### SYMPTOMS

---

- Severe photophobia/discontinued driving
- Pain
- Discomfort especially when waking
- Blurry vision

### PRE TREATMENT

---

- Moist hot compresses: EyeCloud 20mins/day
- EyeSeals 4.0
- Ocunox Ointment QHS
- Hylo Gel
- Moisture Release Goggles with Computer

### TREATMENT

---

Treatment with moist heat.

Lumecca-I and Forma-I with Meibomian Gland expression.

EyeSeals 4.0 solved all overnight dry eye issues.

### IMPROVED DIAGNOSTICS

---

NIK BUT:

Pre-Tx OD **4.77** improved to **22.74** (post Tx)

### RESULTS

---

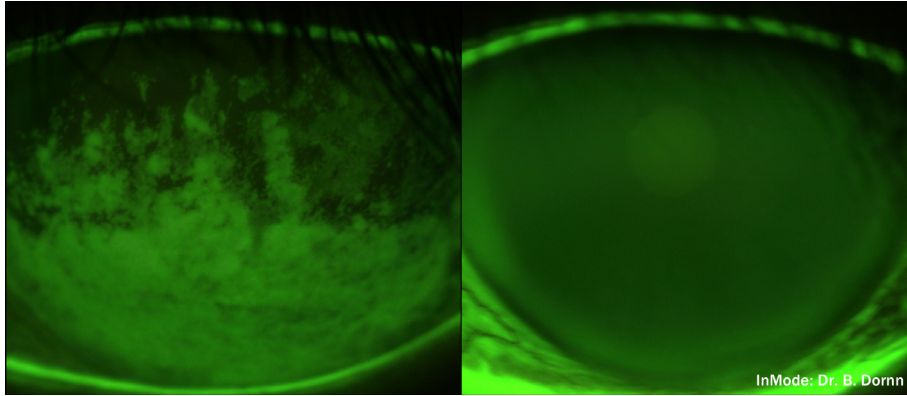
Patient is very happy with comfort and visual acuity at follow up with annual exam.

NIK BUT: Keratitis completely resolved.

Patient manages all symptoms with at-home treatment.

Pre-TX Keratitis

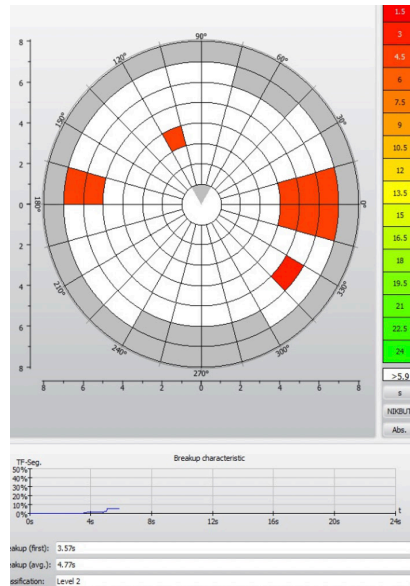
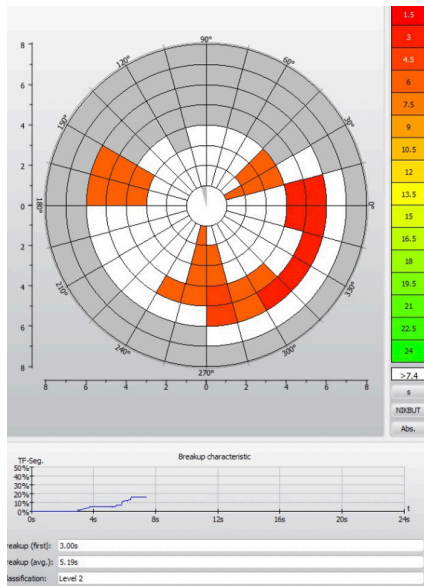
Post-TX Healthy Cornea



NIK BUT PRE-TREATMENT

LEFT NIK BUT : 5.19

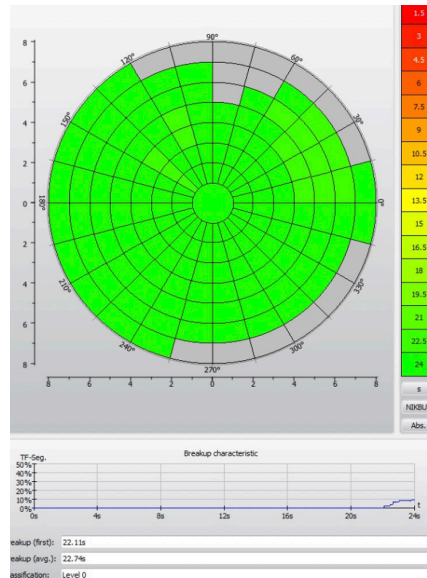
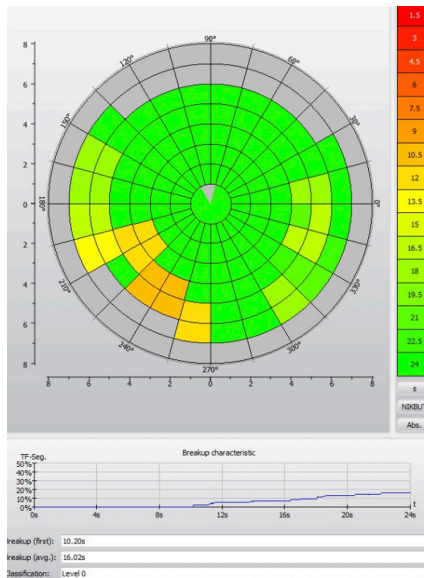
RIGHT NIK BUT : 4.77



NIK BUT POST RF AND IPL TREATMENT

LEFT NIK BUT : 16.02

RIGHT NIK BUT : 22.74



# CASE STUDY 3 :

## Demodex/Blepharitis

DIAGNOSIS: SYSTEMIC LUPUS ERYTHEMATOSUS (SLE)  
AND FLUORESCEIN PHOTO WITH LISSAMINE GREEN STAINING

Age: 53 yrs old  
Gender: Male  
Fitzpatrick: Skin Type 2

### HISTORY

Chronic blepharitis resistant to treatment (patient has been treated with Azithromycin and FML with small improvement in symptoms).

**Medical:** Hypertension  
Systemic chemotherapy  
Non-insulin-dependent diabetes

**DEQ Score:** 53 (severe)

*Referral from Ophthalmologist.*

### SYMPTOMS

- Chronic red eyes
- Tearing eyes
- Crusty lashes
- Chronic foreign body sensation

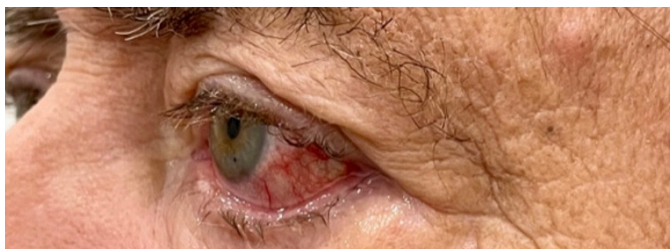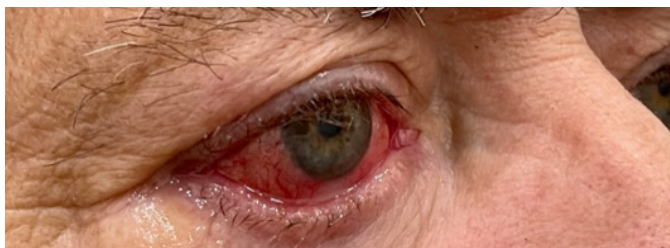
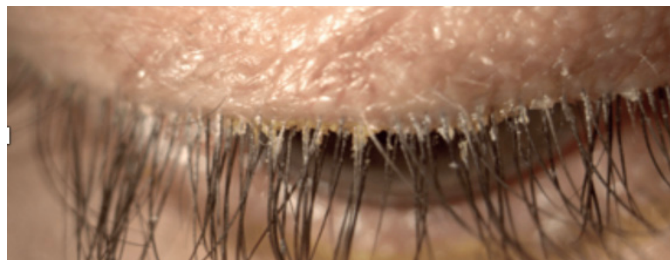### TREATMENT

Lumecca-I: 2 passes OU on upper and lower lids. Total of 4 treatments, 4 weeks apart.

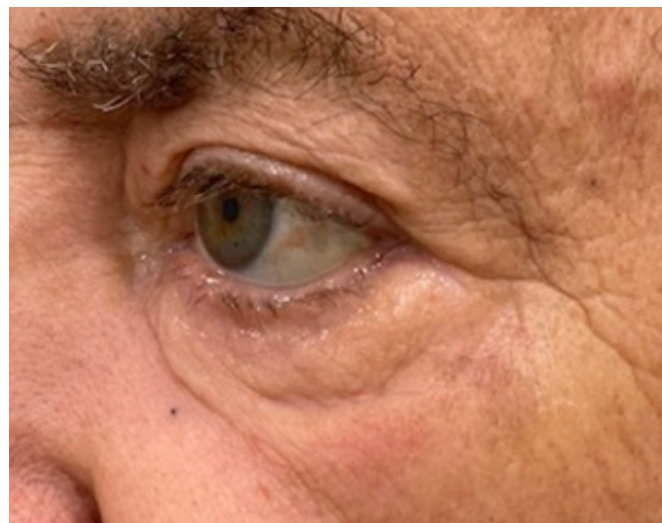Note: The exoskeleton of the Demodex will selectively rapidly absorb IPL energy making Lumecca-I an excellent treatment for Demodex/Blepharitis patients.

### RESULTS

Resolution of Demodex/Blepharitis and red eyes in patient.



Before



After

# CASE STUDY 4 :

## Ocular Rosacea + Medical Aesthetics for Redness on Cheeks

DIAGNOSIS: OCULAR ROSACEA WITH KERATOCONJUNCTIVITIS SICCA

Age: 74 yrs old  
Gender: Male

### HISTORY

Reports chronic tearing and cloudy vision.  
Eyes are sore and often itchy when waking up.

### TREATMENT

Forma-I and Lumecca-I (lids and cheeks) with  
manual gland expression.

Lumecca-I on lids (2 passes) upper and lower  
lids as well as Lumecca on entire cheek area  
(2 passes).

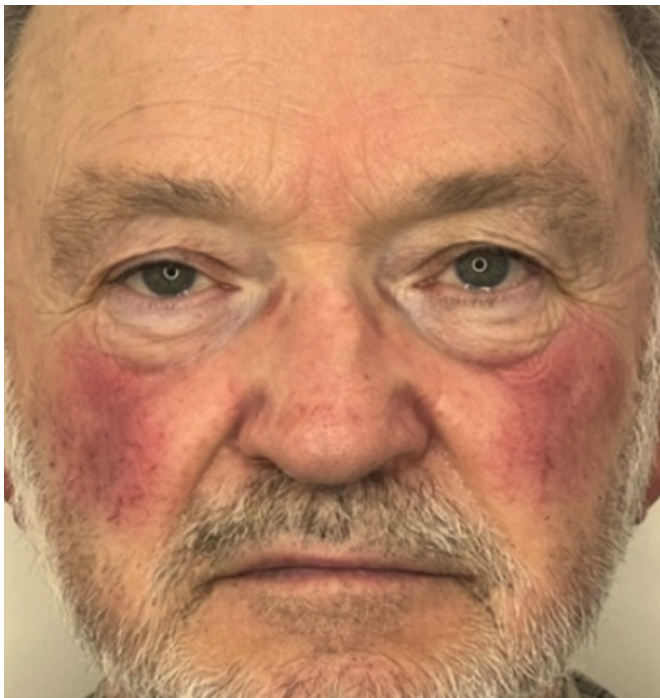Total 4 Treatments, 1 month apart.

### SYMPTOMS

- Tearing
- Blurry vision
- Chronic foreign body sensation

### RESULTS

Patient reports increased comfort with eyes,  
and overall vision improvements. Ocular  
and facial rosacea was managed through  
treatment.



Before  
October 2021



After  
August 2022

# CASE STUDY 5 :

## Chalazion

DIAGNOSIS: CHALAZION

Age: 23 yrs old

Gender: Female

### HISTORY

Chronic lump on upper left eyelid treated by her family doctor for two weeks with Tobradex QID drops and hot compress with no improvement.

### TREATMENT

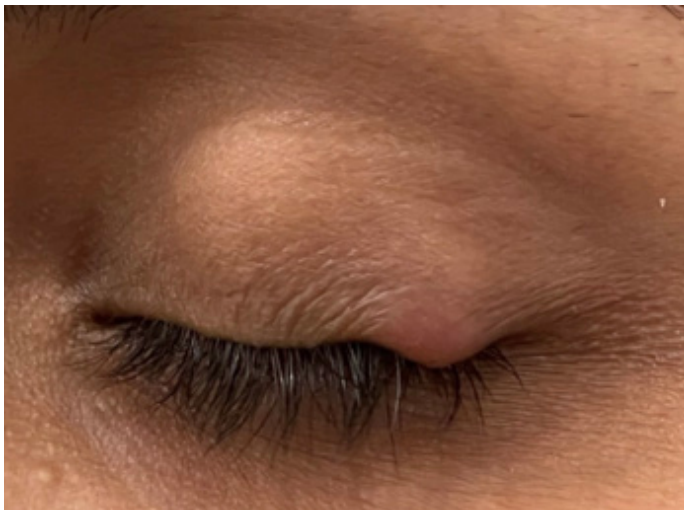Forma-I for 10 minutes over the lid lesion followed by manual gland expression (anesthetic: 2% Xylocaine jelly)  
3 total treatments, 7 days apart, with excellent resolution.

### SYMPTOMS

Hard painless lump on the lid with foreign body sensation while blinking.

### RESULTS

Chalazion bump and redness resolved without the need for surgery.



Before



After



# CASE STUDY 6 :

## Meibomian Gland Dysfunction (MGD) + Hooded Lids

DIAGNOSIS: KERATOCONJUNCTIVITIS SICCA AND DERMATOCHALASIS

Age: 73 yrs old

Gender: Female

### HISTORY

Referral from her Optometrist for dry eyes and unhappy with her droopy eyelids (hooded lids). She was taking Hydrosense drops 4x per day and Restasis 2x per day with no improvement in her symptoms.

### TREATMENT

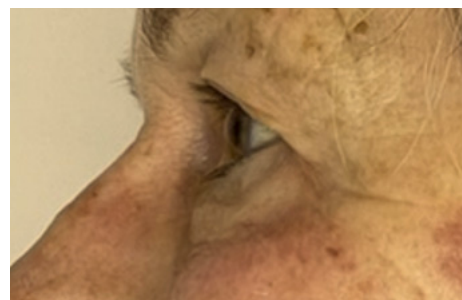
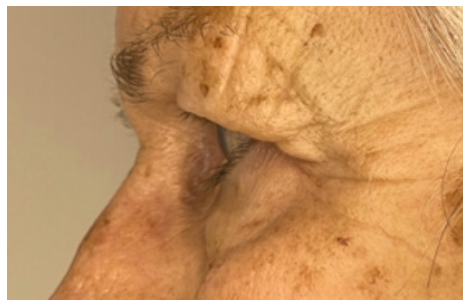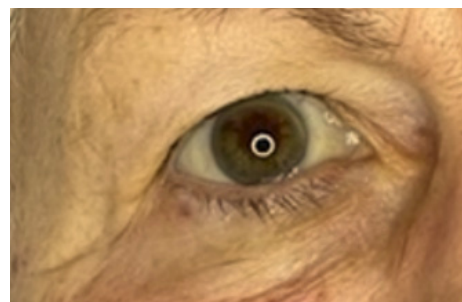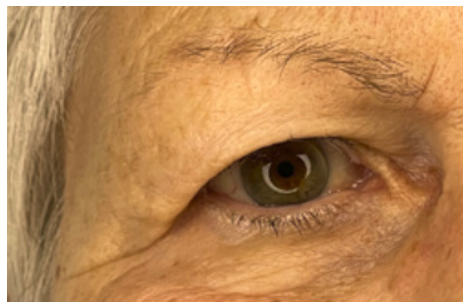
Forma-I 10 minutes per eye (upper and lower eyelids) followed by manual gland expression. Total of 4 treatments, 2 weeks apart.

### SYMPTOMS

- Dry eye
- Sandy/gritty sensation
- Overnight dry eye
- Waking up with ocular discomfort

### RESULTS

Resolution of dry eye symptoms and visible "lifting" of eyelids.



Before

After

# CASE STUDY 7 :

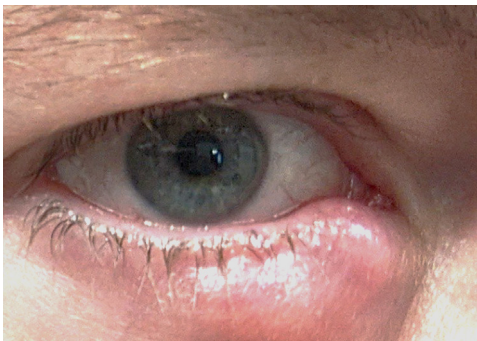
## Ocular Rosacea with Demodex/Blepharitis

### DEMODEX/BLEPHARITIS WITH RECURRENT EXTERNAL HORDEOLUM

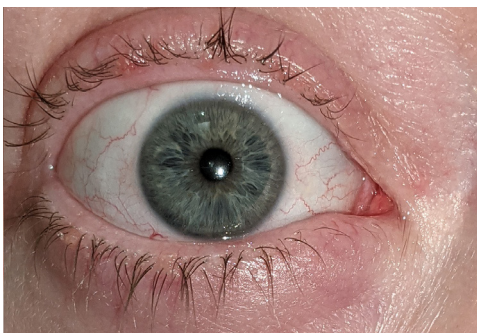
**Age:** 48 yrs old  
**Gender:** Male  
**Occupation:** Professor

#### HISTORY

- Patient has had chalazion excision surgery 7 times.
- Treatment with Doxycycline with significant complications.
- Treatment with Bruder mask and electric mask and reported no improvement and dry eye after treatment.
- Patient states that he would like any treatments other than surgery to address his continuous dry eyes and stye formation.



Before



After

#### SYMPTOMS

- Chronic red, sore eyes
- Chronic “styes”
- Burning eyes
- Blurry vision

#### TREATMENT

##### Office Treatment:

- Forma-I and Lumecca-I combination therapy with manual expression of chalazion
- Blepharitis

##### At Home Pre-Treatment:

- Moist hot compress: EyeCloud 20mins/day
- 2% Tea Tree Cleanser
- Hylo Dual drops 4 times per day OU
- E9 for contact dermatitis as needed

#### DIAGNOSTIC TOOLS

- K5M
- Slit lamp examination
- Inflammadry

#### RESULTS

- Excellent outcome with resolution of chalazion without surgery.
- Patient has maintained results with moist heat 20 minutes once a day and TTF 2% OU once a day.
- Patient maintains good health with a Lumecca-I treatment once every 6 months.

*He reports no stye or chalazion formation for the last three years.*





# DORNN EYE CARE

DR. BRUCE DORNN • OPTOMETRIST